P9

DIAGNOSTIC APPROACH TO HARLEQUIN SYNDROME: A CASE REPORT

Aben A., Verhaeghe E., De Schepper S., Beele H., Hoorens I.

Department of dermatology, University Hospital Ghent, Ghent, Belgium

INTRODUCTION: DO YOU KNOW THIS SYNDROME?

Harlequin syndrome, first described in 1988 by Lance et al. [1], is a remarkable condition characterized by unilateral decreased flushing and anhidrosis of the face, due to damage of the sympathetic fibers on the ipsilateral side. Paradoxally, the unaffected side displays a compensatory overreaction to provide normal heat regulation, resulting in an asymmetry in facial appearance with a distinct line between the affected pale half and the unaffected red half following to a thermal or emotional stimulus [1-3].

CASE DESCRIPTION

We report a case of a **56-year-old woman** with a history of **three episodes of unilateral flushing** and sweating on the right side of the face in a period of two years. All three episodes took place when the patient was submitted to prolonged physical exercise in a warm environment. The left side of the face remained anhidrotic and maintained its normal color. There were no pupil abnormalities.

- **Medical history:** Blank, besides a known Tarlov cyst in the sacral region
- **Diagnostic work-up:** Reassuring, including:
  - Clinical neurological evaluation
  - Imaging: chest X-Ray, carotid Duplex and MRI brain and cervicothoracic region
- **Diagnosis:** Idiopathic harlequin syndrome
- **Treatment:** None required

Figure 1: *First episode of unilateral flushing took place while walking along the Belgian seaside during summertime.*

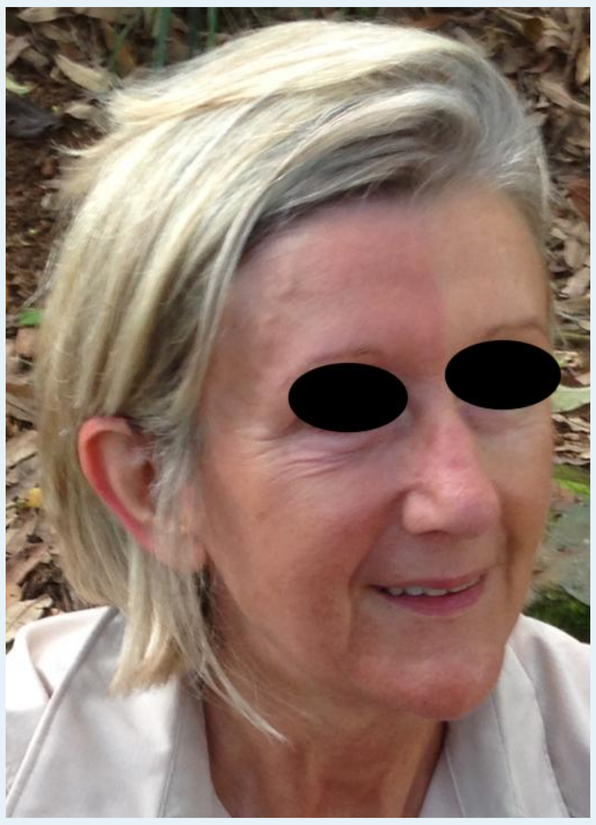

Figure 2: *Second episode of unilateral flushing took place while hiking on a holiday in Vietnam.*

DISCUSSION

PATHOGENESIS

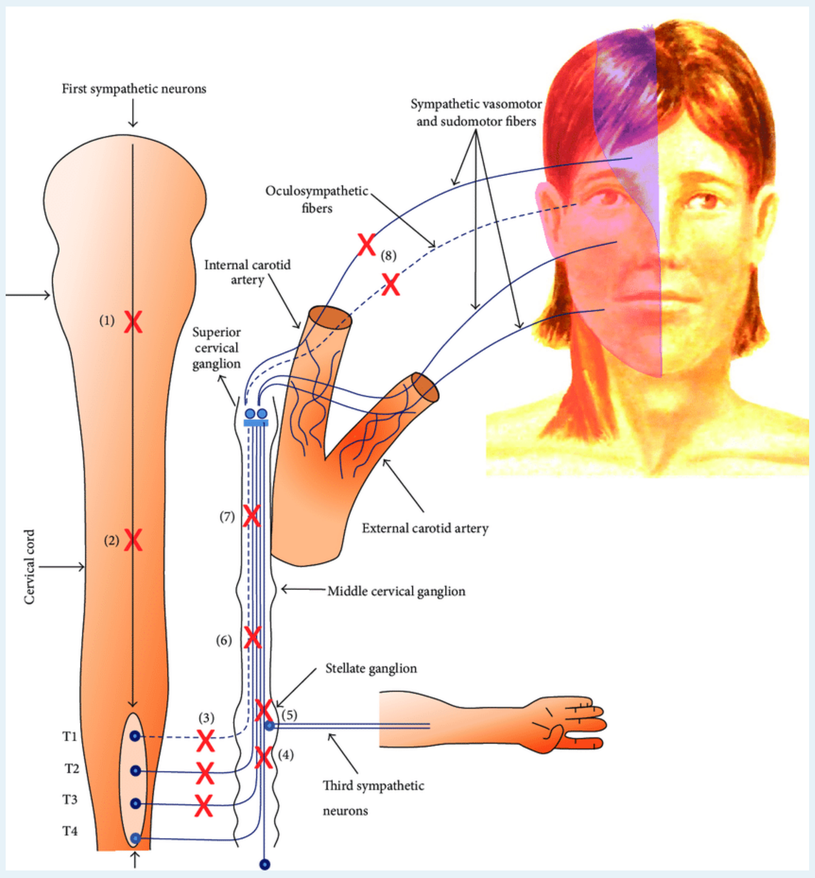

Figure 3: *Sympathetic innervation of the face with possible lesion sites. Adapted from: Algahtani et al. Idiopathic Harlequin syndrome Manifesting during Exercise: A Case Report and Review of the Literature. Case Rep Med.2017 [4].*

The vaso- and sudomotoric innervation of the face originates in the hypothalamus (first-order neuron). The sympathetic fibers synapse in the lateral horn of the spinal cord with the preganglionic (second-order) neurons. At T2-T3 they exit the spinal cord, then go through the sympathetic trunk to synapse in the superior cervical ganglion. The postganglionic fibers (third-order neuron) reach and pass the carotid plexus to arrive at their effector cells on the ipsilateral side of the face [4].

According to the picture above, **dysfunction may be located at any of the three levels in the cervical sympathetic trunk** [4]**:**

(1) Lesions within the pons
(2) Lesions within the spinal cord
(3) Lesions within the thoracic roots T1-T3
(4) Sympathicus between T1-T2
(5) Stellate ganglion
(6) Trunk between stellate and middle cervical ganglion
(7) Trunk between middle and superior cervical ganglion
(8) Sympathetic fibers traveling with the carotid artery

CAUSES

Hemifacial loss of flushing and anhidrosis is caused by unilateral damage to or blockage of the ipsilateral sympathetic fibers, responsible for the innervation of the same side of the face. As a consequence, there is an inability of the facial vasculature to dilate in response to thermal or emotional stimuli. This also causes an overreaction on the contralateral side of the face with excessive flushing [1-4].

In most cases Harlequin syndrome is **idiopathic,** but in one out of six cases it is the first symptom of an **underlying disorder or structural lesion**. Harlequin syndrome can also be **iatrogenic**, due to previous invasive procedures [2-4].

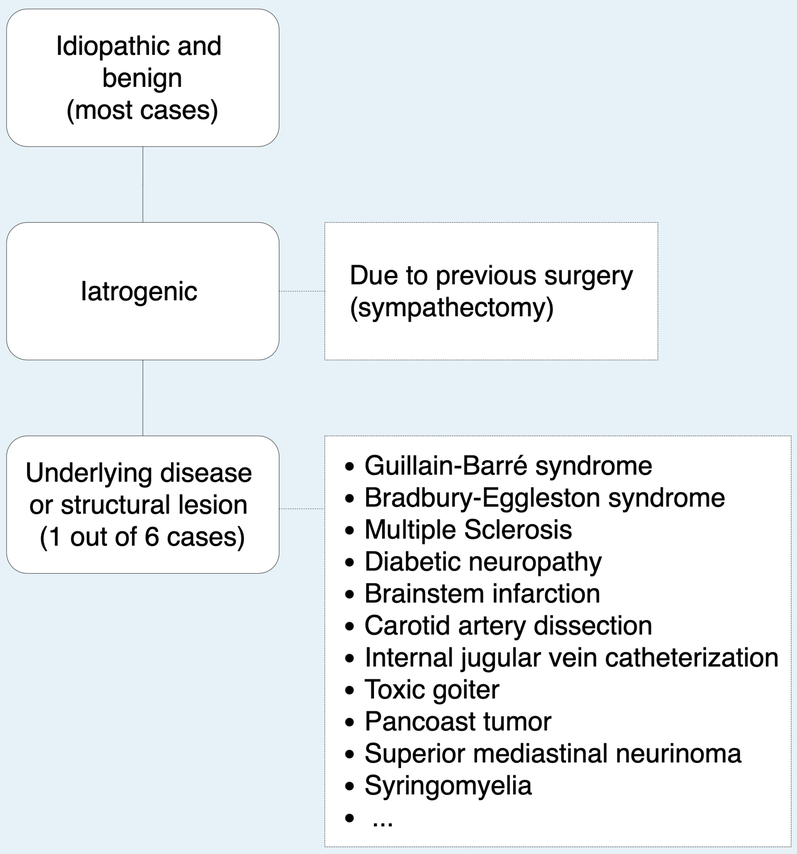

Figure 4: *Causes of Harlequin syndrome*

DIAGNOSTIC APPROACH

If there is no history of sympathectomy, a **clinical neurological evaluation** (with special attention to pupillary responses to make a distinction with Horner syndrome) should be performed. Necessary **imaging** to exclude an underlying disease or lesion includes Duplex ultrasonography of the supra-aortic trunks and magnetic resonance imaging of the brain and the cervicothoracic region [1-4].

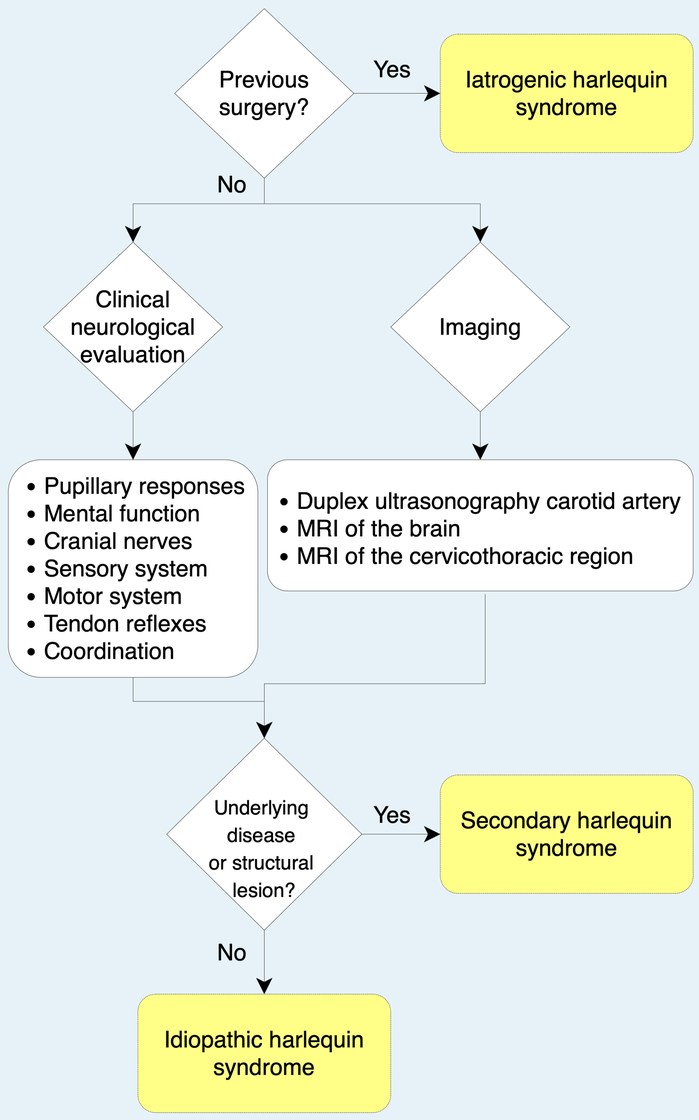

Figure 5: *Diagnostic approach to Harlequin syndrome*

TAKE HOME MESSAGES

- Although it is quite rare, dermatologists should be aware of the existence of Harlequin syndrome and its presence should alert the clinician to further investigate for an underlying cause.
- Most cases are idiopathic and benign, but nevertheless distressing for patients and a diagnostic challenge for clinicians.

REFERENCES

1. Lance JW et al. Harlequin syndrome: the sudden onset of unilateral flushing and sweating. J Neurol Neurosurg Psychiatry. 1988; 51:635-642.
2. Hans-Bittner NR et al. Do you know this syndrome? Harlequin syndrome. An Bras Dermatol. 2018; 93(4):585-586.
3. Zabalza Estévez RJ et al. Harlequin syndrome, a rare neurological disease. Neurologia. 2015; 30(3):185-7
4. Algahtani et al. Idiopathic Harlequin Syndrome Manifesting during Exercise: A Case Report and Review of the Literature. Case Rep Med. 2017.

UZ GENT
UNIVERSITEIT GENT

Contact
Department of dermatology
+32 (0)9 332 22 87
aurelie.aben@uzgent.be