

Dyshidrotic hand dermatitis from a copper-containing intra-uterine device

Hannelore GEORGE, Ella DENDOOVEN, Olivier AERTS

Dermatology,
University Hospital Antwerp
(UZA), Belgium

BACKGROUND

- Copper is widely present in the environment (e.g. coins)
- Copper only rarely provokes allergic contact dermatitis
- Apart from skin exposure, the mucosae may be exposed to it
 - Oral: **dental material**
 - Genital: **intra-uterine devices (IUDs)**
- The popularity of copper IUDs is increasing ~ "hormonophobia"

CASE REPORT

- Nonatopic 22y ♀ episodes of dyshidrotic eczema hands/feet
- Started 1 month after placement of copper IUD
- Topical corticosteroids insufficient
- **Patch tests**
 - Nickel 5% pet ++
 - **Copper(II)sulfate pentahydrate 2% pet ++**
 - IUD 'as is' -
 - **Aqueous extract of copper IUD +**
 - **Pieces of copper IUD soaked in water +/IRR**
 - Flare-up of dermatitis during patch test week
- Removal of the copper IUD relieved the symptoms

DISCUSSION

- **Systemic contact dermatitis** from pharmaceutical drugs and plant products (e.g., herbal teas, spices) is well-known
- The clinical presentation can be a generalized dermatitis, but also a (recalcitrant) **dyshidrotic dermatitis**
- **Metals** can also cause systemic contact dermatitis (e.g., nickel, cobalt in vit B12 food supplements)
- **Copper**
 - Rare skin sensitizer
 - In dental applications: lichenoid stomatitis
 - In IUDs: systemic contact dermatitis:
 - Present case
 - Multiple historical cases (1978-1996)

PICTURES

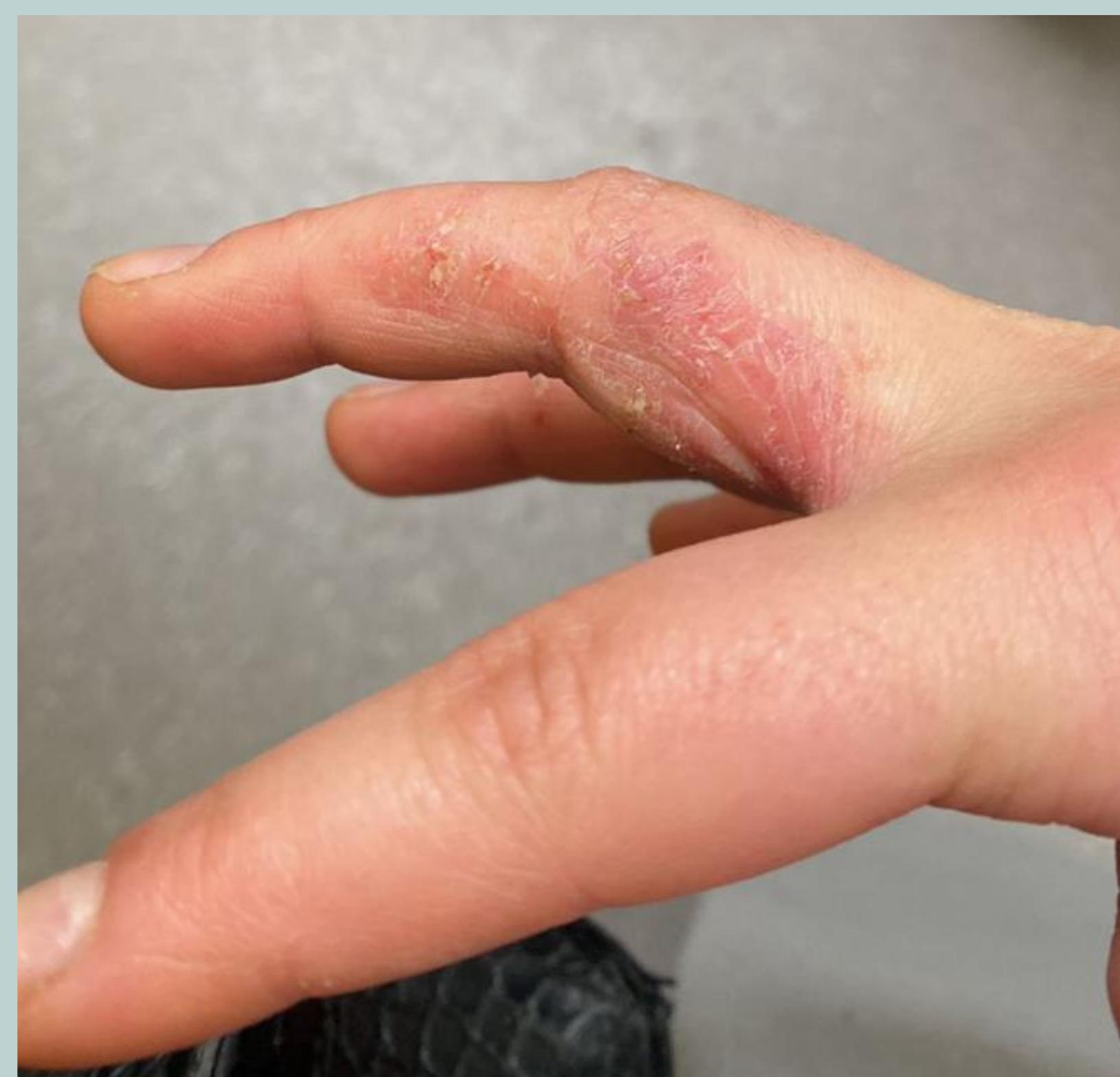

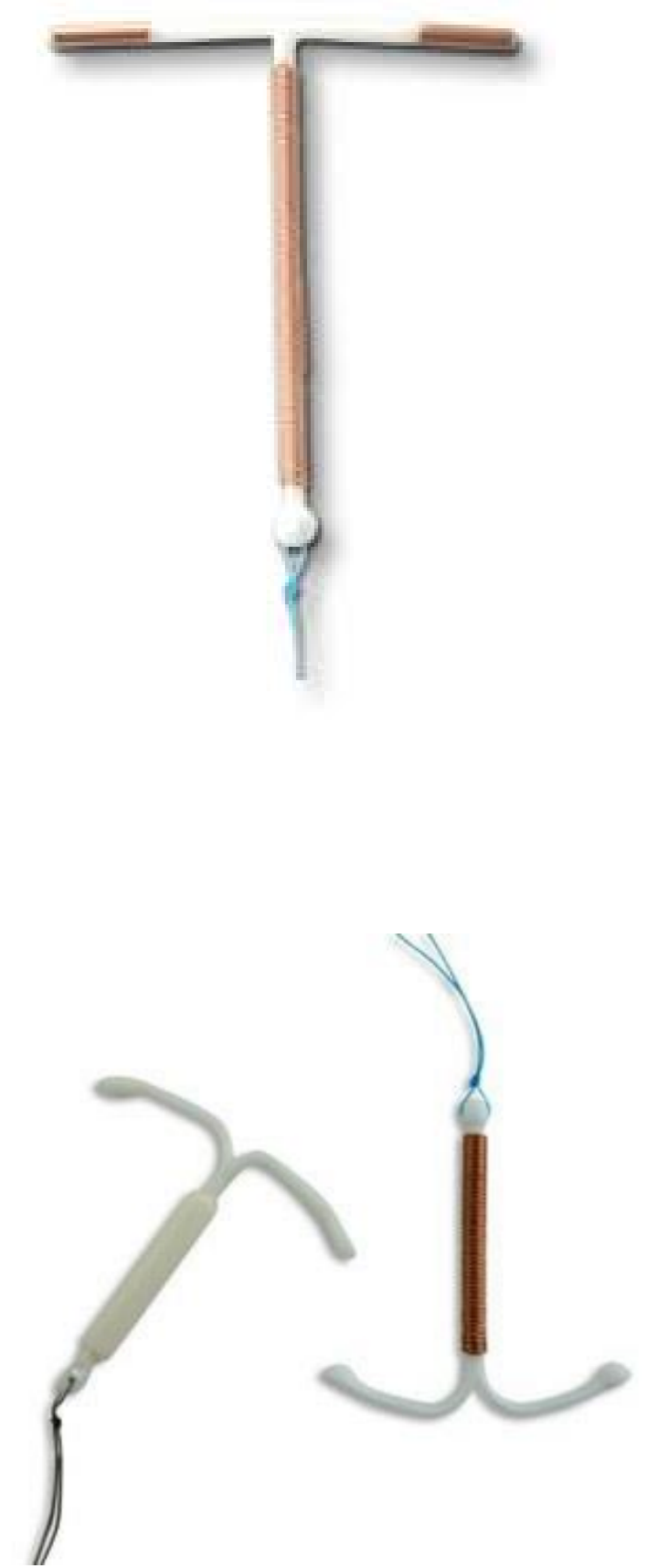
Figure 1: Dyshidrotic eczema of the hands since >6 months

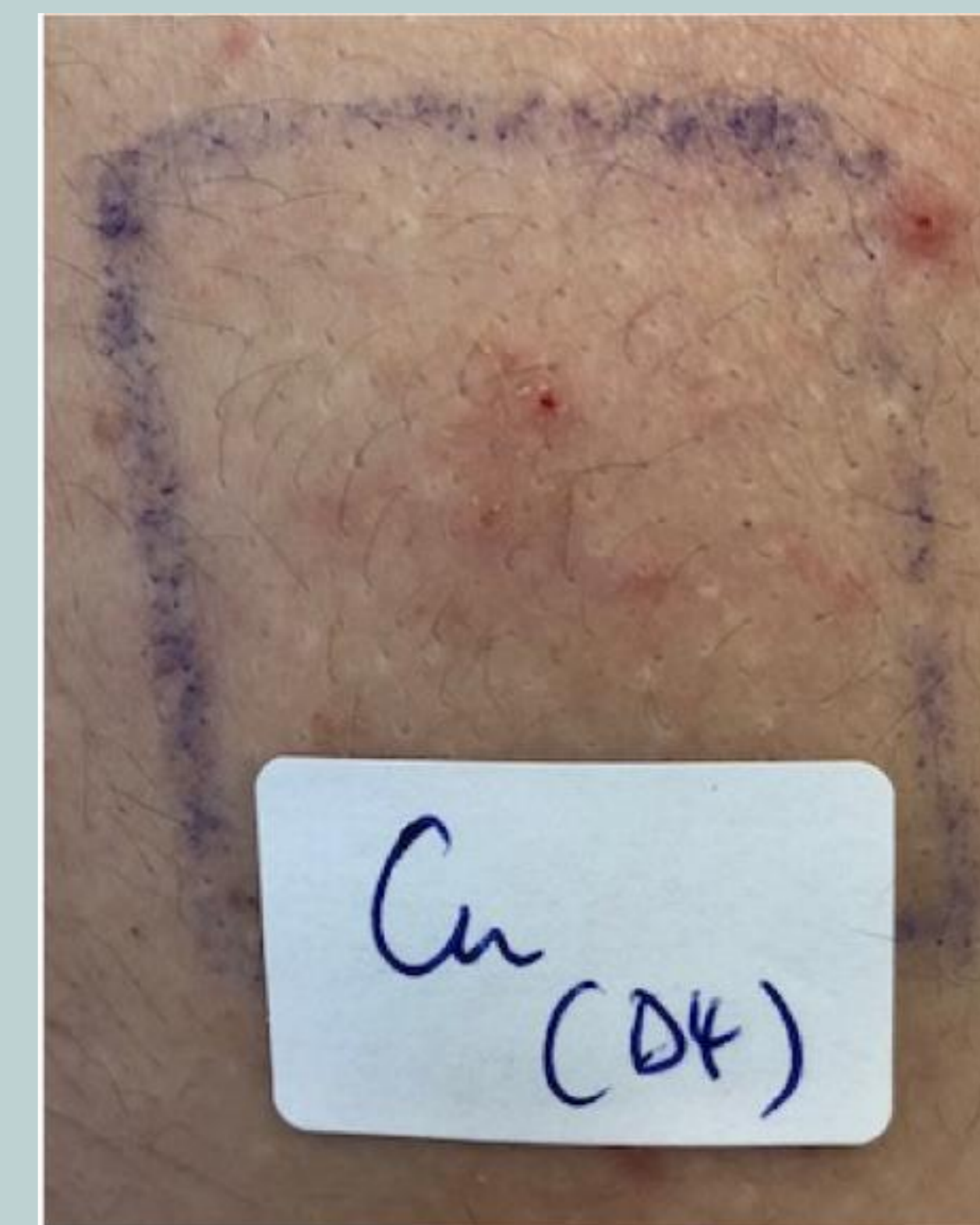

Figure 2: Positive patch test reaction to copper(II)sulfate 2% pet

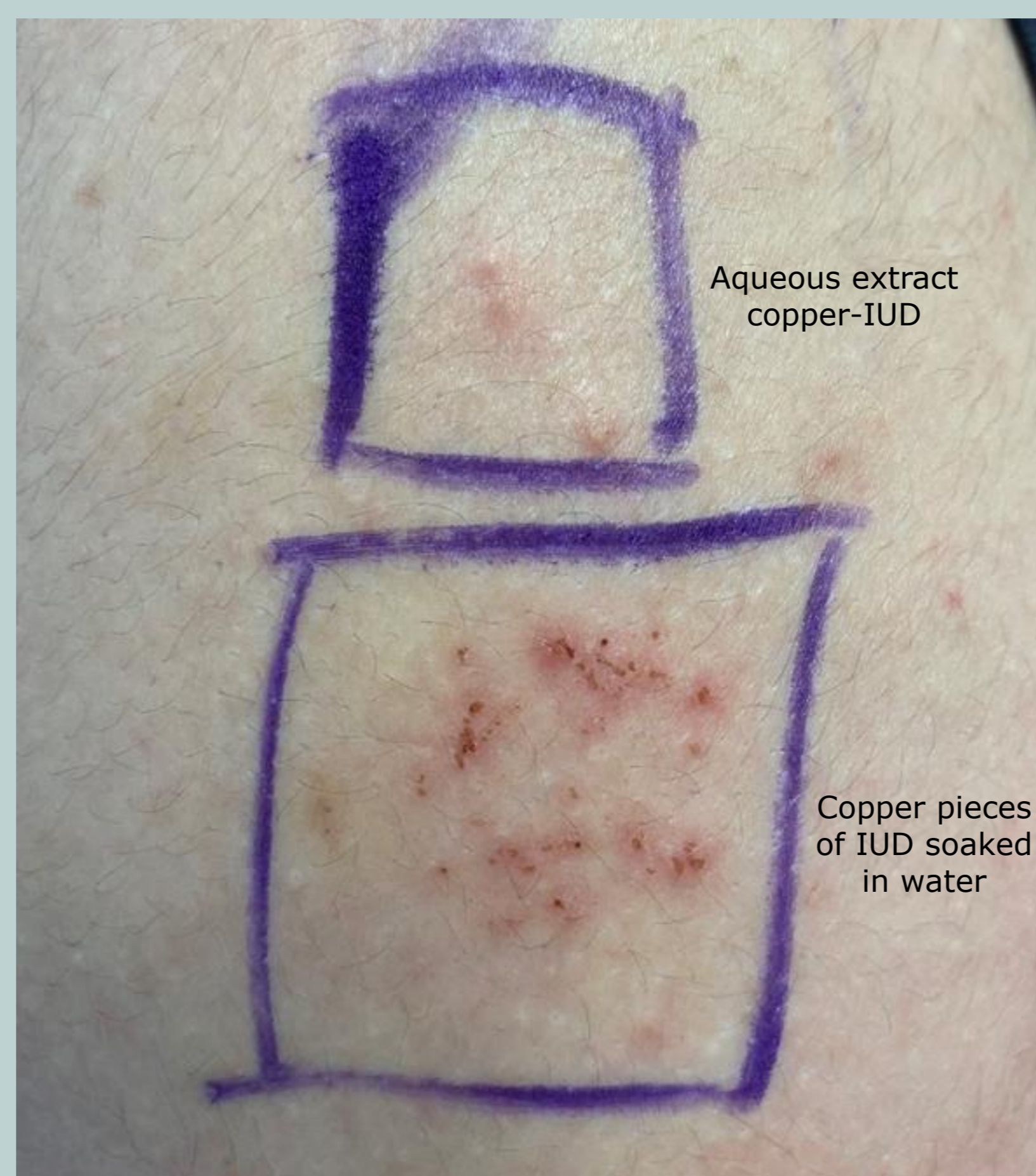
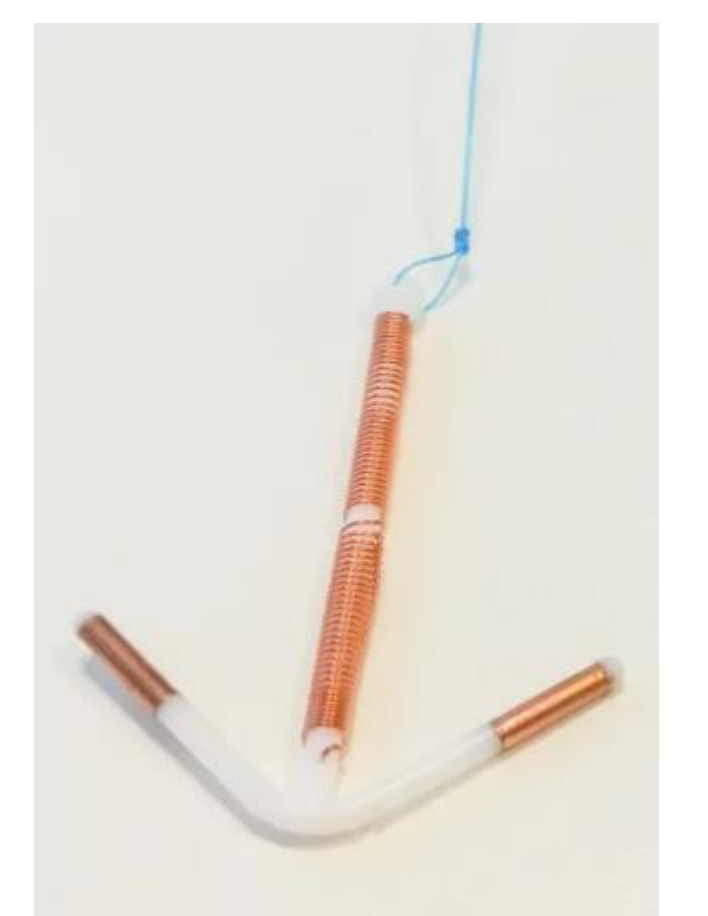
Figure 3: Positive patch test reactions to a water extract of copper pieces, and to the (soaked) copper pieces



REFERENCES

1. Fage SW, Faurschou A, Thyssen JP. Copper hypersensitivity. Contact Dermatitis. 2014;71(4):191-201.
2. Gomez AM, Freihart B. Motivations for interest, disinterest and uncertainty in intrauterine device use among young women. Matern Child Health J. 2017;21(9):1753-1762.
3. de Groot AC. Systemic allergic dermatitis (systemic contact dermatitis) from pharmaceutical drugs: a review. Contact Dermatitis. 2022; 86(3):145-164.
4. Yoshihisa Y, Shimizu T. Metal allergy and systemic contact dermatitis: an overview. Dermatol Res Pract. 2012;2012:749561.
5. Pegalajar-García MD, Cebolla-Verdugo M, Prados-Carmona A, Llamas-Segura C, Navarro-Triviño FJ. Systemic allergic dermatitis to cobalt present in cyanocobalamin supplementation. Contact Dermatitis. 2023;89(3):203-205.

CONCLUSIONS

- **Copper is a rare skin sensitizer...**

BUT ...

- ... think of a "systemic contact dermatitis" to copper when confronted with women with unexplained dermatitis (generalized or dyshidrotic) after placement of a copper-containing IUD

Presented at the Belgian Dermatology Days (BDD) 2024

Contact:

- Hannelore.george@uza.be
- Ella.dendooven@uza.be
- Olivier.aerts@uza.be